AGRICULTURAL BIOLOGY,
2019, V. 54, № 6, pp. 1154-1166
(SEL'SKOKHOZYAISTVENNAYA BIOLOGIYA)

ISSN 2412-0324 (English ed. Online)
ISSN 0131-6397 (Russian ed. Print)
ISSN 2313-4836 (Russian ed. Online)

UDC 636.93:636.085.8:591.1

doi: 10.15389/agrobiology.2019.6.1154eng
doi: 10.15389/agrobiology.2019.6.1154rus

PHYSIOLOGICAL STATUS AND FUR QUALITY OF YOUNG SILVER FOXES (*Vulpes vulpes* L.) UNDER USE OF ANTIPARASITIC DRUG NIACID-GRANULES PLUS AND BIOACTIVE KERATIN AS A FEED ADDITIVE

A.I. SAPOZHNIKOVA[1], K.V. ESEPENOK[1], G.Yu. KOSOVSKY[2], E.A. TINAEVA[1], M.N. MIRZAEV[1], E.G. KVARTNIKOVA[2], B.V. NOVIKOV[2], T.M. CHEKALOVA[2]

[1]*Skryabin Moscow State Academy of Veterinary Medicine and Biotechnology*, 23, ul. Akademika K.I. Skryabina, Moscow, 109472 Russia, e-mail fibrilla@mail.ru (✉ corresponding author), opusek@icloud.com, niacid@yandex.ru, tinaevaea@list.ru;
[2]*Afanas'ev Research Institute of Fur-Bearing Animal Breeding and Rabbit Breeding*, 6, ul. Trudovaya, pos. Rodniki, Ramenskii Region, Moscow Province, 140143 Russia, e-mail gkosovsky@mail.ru, liza.kvartnikova@mail.ru, bnovikov@mail.ru, tamilachekalova@yandex.ru
ORCID:
Sapozhnikova A.I. orcid.org/0000-0001-5040-6998
Esepenok K.V. orcid.org/0000-0002-3085-6577
Kosovskii G.Yu. orcid.org/0000-0003-3808-3086
Tinaeva E.A. orcid.org/0000-0002-3454-540X
Mirzaev M.N. orcid.org/0000-0002-7093-1711
Kvartnikova E.G. orcid.org/0000-0002-5009-0353
Novikov B.V. orcid.org/0000-0002-8850-315X
Chekalova T.M. orcid.org/0000-0002-5476-9750
The authors declare no conflict of interests
Received September 29, 2019

Abstract

Recently, among carnivores, including silver-black foxes, cases of nematode infestation have become more frequent, causing significant economic damage. From helminthic infestations, youngsters suffer the most. Currently, in the veterinary world practice, anthelmintics of the new generation, in particular, avermectin-based products are recognized the most promising. To date, neither in Russia nor abroad, keratin preparations in combination with anthelmintics have been used in fur farming. In the present work, it was experimentally proved for the first time that a new-generation anthelmintic Niacid-Granules Plus combined with a sulfur-containing feed additive Bioactive Keratin improve fur grading indices (size, amount of fur, completeness of fur, damage to fur, damage to skin etc.) in silver-black foxes (*Vulpes vulpes* L.). This paper documents physiological effects and fur quality parameters in young silver-black foxes due to the combined use of Bioactive Keratin and an avermectin-based anthelmintic. Niacid-Granules Plus (LLC SPA Ecobiovet, Russia, and Skryabin Moscow State Academy of Veterinary Medicine and Biotechnology, Russia) are brown granules, 300-400 g per pack, with 85 % abamectin B_{1a} and 15 % abamectin B_{1b} contents and the allowed shelf life for at least 21 months. Bioactive Keratin (Skryabin Moscow State Academy of Veterinary Medicine and Biotechnology, Russia) is a monoproduct derived from tow of wool and containing 98 % of native protein, a preparative form of homogeneous liquid mass, color from light gray-beige to dark gray-beige, with a specific smell, mass fraction of dry matter 3-10 %, mass fraction of keratin 95-98 %, and a shelf life of not more than 2 years. The preparations Niacid-Granules Plus and Bioactive Keratin belong to the IV class of toxicity. It is shown that the combined use of Niacid-Granules Plus and Bioactive Keratin significantly enhances the effect of each drug used separately. In farm tests (AO Saltykovskii Breeding Farm, Moscow Province, 2017-2018), it was found that deworming young silver-black foxes at the age of 2 months with Niacid-Granules Plus and the subsequent use of dietary Bioactive Keratin as a sulfur-containing feed additive significantly affect body weight gain in foxes. Under the combined use of Niacid-Granules Plus and Bioactive Keratin, the live body weight of pups is 9.1 % higher compared to the control ($t_{fact.} = 7.40 \geq t_{tab.} = 2.1$ at $p = 0.05$ and $t_{fact.} = 0.81 \leq t_{tab.} = 2.1$ at $p = 0.05$, respectively). Niacid-Granules Plus together with Bioactive Keratin also improved the complete blood counts during the investigation, thereby contributing to a faster normalization of the physiological status of young silver-black foxes. When using both drugs, the weight of young silver-black foxes increased by 30.4 %, the area of the obtained furs by 18.4 %, the hair density by 24.6 % compared to these parameters in intact animals. This confirms the effectiveness of the joint use of the studied preparations. The use of Niacid-granules plus are allowed to animals at the age of 2 months, twice at 10-day interval, and the dietary Bioactive Keratin should be added to feed in six cycles (5-day cycles

with 10-day intervals).

Keywords: *Vulpes vulpes* L., silver fox, young animals, Niacid-granules plus, avermectin, bioactive keratin, body weight gain, blood indicators, fur quality

In fur-bearing animals [1], the formation of animal hair and the quality of skin due to breed characteristics depend on the physiological state of animals, which, in turn, is determined by feeding conditions [2], maintenance [3], preventive and therapeutic measures [4]. In recent years, among carnivores, including silver-black foxes, cases of nematode infestations have become more frequent. Young animals suffer especially severely from helminthic infestations. As a rule, helminthic diseases cause exhaustion, the reproductive ability of animals decreases, growth and development of young silver-black foxes and other carnivores decelerates [5, 6]. In fur-bearing animals, more than 70 species of various nematodes can parasitize [7]. Toxocariasis, toxascaridosis, and trichinosis are of the greatest economic importance. Despite the fact that at present there is a fairly wide range of anthelmintic agents (for example, Ivomek®, ZAO Nita-PHARM, Russia; Nilverm®, Pliva, Croatia; Albamelin®, AO Veterinary Preparations, Russia), helminthic infestations cannot be completely defeated. It is known that any anthelminthic preparation destroys only adult worms, while helminth eggs remain in the body even after deworming. Therefore, with the established fact of helminthic infestation, it is required to conduct 2-fold treatment of animals with an interval of 10 days so that by the time of the second treatment, immature animals that are not able to produce their offspring will have appeared from eggs [5].

The most promising anthelmintic preparations of the new generation are, in particular, avermectin-based products [8-10]. The Niacid-Granules Plus preparation (LLC SPA Ecobiovet, Skryabin Moscow State Academy of Veterinary Medicine and Biotechnology, Russia) is one of the latest developments in the line of anthelmintics of the avermectin series [10], however, it has not yet been used in animal farming. According to the mechanism of action, this is a neurotoxin-type drug (the active substance blocks and inhibits the transmission of a nerve impulse, causing paralysis and then death of nematodes) [8].

Earlier, the authors examined various areas of practical application of keratin-containing preparations [11], in particular, in cosmetology and medicine [12-14]. Preparations of hydrolyzed keratin can be used in animal husbandry [15], as well as in fur breeding as active feed additives that affect the condition of the hair of the skin [11]. The hydrolyzed keratin contains the amino acid cysteine, which refers to thiol compounds. The mechanism of biochemical action of thiols consists in the ability to restore disulfide bonds in pathological disorders, inactivate toxic agents, and also increase the content of sulfhydryl groups, providing an antioxidant effect [16, 17]. Thiol compounds are primarily exposed to active oxygen radicals, which protects the functional groups of biological molecules and cell membranes from their influence [18, 19].

To date, keratin preparations in combination with anthelmintic preparations have not been used in the industrial breeding of fur-bearing animals, although the complex use of biologically active substances [20-22] and veterinary drugs is recognized as highly effective (Vidal Veterinarian 2019. Medicines for Veterinary Applications in Russia. Moscow, 2018). However, the data on the effectiveness of these substances, their doses [23], and the characteristics of the effect on fur-bearing animals, in particular silver-black foxes, are extremely limited and quite fragmented (24). In individual publications, the separate use of keratin on minks was reported (O.V. Barantseva, Technology for the preparation of keratin-containing feed additives and assessment of its effect on the quality of

mink's skin. Cand. Dis. Moscow, 2011), as well as the use of keratin, collagen and melanin on ferrets [11].

In the present work, it was experimentally proved for the first time that a new-generation anthelmintic Niacid-granules plus combined with a sulfur-containing feed additive Bioactive keratin, the keratin-containing waste recycling product, improve fur grading indices (size, amount of fur, completeness of fur, damage to fur, damage to skin etc.) in silver-black foxes

The purpose of the work is to determine the physiological effect of the combined use of bioactive keratin and anthelmintic based on avermectin in the growing young silver-black foxes and to evaluate the quality of the obtained skin products.

Techniques. In the experiment, we used the preparation Niacid-Granules Plus (LLC SPA Ecobiovet) and Bioactive Keratin (Skryabin Moscow State Academy of Veterinary Medicine and Biotechnology) from tow of fine sheep wool (reusable waste from wool processing in the textile industry) [25].

The toxicity of the drug Niacid-Granules Plus and the feed additive Bioactive Keratin was evaluated according to GOST 12.1.007-76 Harmful Substances. Classification and General Safety Requirements, as well as on the basis of the requirements set forth in GOST 32296-2013 Methods of Testing Chemical Products on the Human Body. Basic Requirements for Conducting Tests to Assess Acute Toxicity for Intragastric Administration by the Fixed-Dose Method. As experimental laboratory animals, 70 random-bred white mice and 70 outbred Wistar rats assigned to groups of analogs by live weight were used. The experiments were conducted in accordance with the protocols of the Geneva Convention and the principles of proper laboratory practice (National Standard of the Russian Federation GOST R 53434-2009), as well as according to the recommendations of The Guide for the Care and Use of Laboratory Animals (National Academy Press Washington, DC 1996). Mean lethal doses were calculated [26].

To evaluate the effectiveness of separate and combined use of anthelmintic preparation and bioactive feed additive, 2-month-old silver-black foxes (*Vulpes vulpes* L.) were divided into 4 groups of 10 animals by the methods of analogs using birth dates and live weight (AO Saltykovskii Breeding Farm, 2017). The drugs were given to animals in accordance with the following scheme: in Group I, the anthelmintic preparation Niacid-Granules Plus was added twice to the animals' BD accepted at the farm (AI 200 μg/granule per 1 kg of animal weight, with an interval of 10 days, starting from the 1st day of the experiment); in Group II, the anthelmintic preparation Niacid-Granules Plus in the same dose and the preparation Bioactive Keratin in the amount of 0.2% of the daily protein norm (6 cycles, including 5-day courses with 10-day intervals) were added to the BD; Group III (control) consisted of intact animals that did not receive the anthelmintic preparation and the feed additive, Group IV was intact animals, in the BD of which the drug Bioactive Keratin was added in an amount of 0.2% of the daily protein norm (6 cycles including 5-day courses with 10-day intervals).

During the observation period, young animals were weighed individually with an accuracy of 0.01 kg (electronic scales MP VD (Zh) A F-2, OOO MIDLiK, Moscow, Russia).

The physiological state of the animals was assessed by the results of the general clinical analysis of whole blood (performed at the laboratory of Moscow Station for the Control of Animal Diseases). The samples were taken from the lateral saphenous vein of a thigh (in the morning after a night's sleep before feeding and drinking) from 2-month-old animals before the start of the experiment and from 7-month-old animals at the end of the experiment. The hemo-

globin content, the total number of erythrocytes and leukocytes, the content and ratio of the main subpopulations of granulocytic leukocytes (lymphocytes, monocytes, eosinophils, neutrophils, and basophils) included in the leukocyte formula were determined.

At the end of the experiment, the obtained skins were subjected to primary processing and a quality assessment commission in accordance with GOST 2790-88, and the basic properties of the skins (area, length, and thickness of hair of various categories) were determined. The thickness of the hair on the rump was determined by direct counting and by the number of hair roots in horizontal sections. Histological sections were prepared according to the standard method with hematoxylin and eosin staining, fixing them at the final stage under a coverslip with Canadian balsam [11], and examined at ×400 magnification (ZEISS Axio Lab. A1, Zeiss AG, Germany).

During statistical processing of the obtained results, the arithmetic mean (*M*) and standard error of the mean (±SEM) were determined. The statistical significance of differences in means was evaluated by Student's *t*-test [27, 28].

Results. Niacid-Granules Plus granules are feed bait supplemented with antiparasitic ingredient (200 μg AI/kg). Characterization of organoleptic, physicochemical and biological properties of the preparation was performed according to the requirements of the State Pharmacopoeia XI [29] (Table 1).

1. Characterization of anthelmintic Niacid-Granules Plus drug (LLC SPA Ecobiovet) [29]

Indicator	Description
Appearance, color	Brown granules weighing 300-400 mg
Authenticity of AI (abamectin):	
avermectin B_{1a}, % (not less)	85
avermectin B_{1b}, % (not more)	15
Mass fraction of abamectin, %	200±20 rg/granule
Toxicity, rat test-dose	IV class of toxicity
Foreign mechanical inclusions	Not allowed
Storage time	Not less than 21 months

As follows from Table 1, the active ingredient of the drug Niacid-Granules Plus is a complex of natural non-hydrogenated avermectins B_{1a} and B_{1b}, which are stable only if the relevant established storage modes are observed [29].

2. Characterization of Bioactive Keratin dietary additive (Skryabin Moscow State Academy of Veterinary Medicine and Biotechnology, Russia) [29]

Indicator	Description
Appearance	Homogeneous liquid mass
Color	From light gray beige to dark gray beige
Smell	Specific
Hydrogen indicator	6.5-7.5
Authenticity	Positive reaction to keratin
Mass fraction of dry matter, %	3.0-10.0
Mass fraction of keratin calculated on the dry matter, %	95.0-98.0
The total number of mesophilic aerobic and facultative anaerobic microorganisms, CFU/1 g (cm^3) of product	Not more than 1×10^2
Yeast, yeast-like, mold fungi in 1 g/cm^3 of product	Absent
Bacteria of the family *Enterobacteriaceae* in 1 g/cm^3 of product	
Bacteria of the species *Pseudomonas aeruginosa* in 1 g/cm^3 of product	Absent
Bacteria of the species *Staphylococcus aureus* in 1 g/cm^3 of product	Absent
Toxicity, rat test-dose	IV class of toxicity
Storage time	No more than 2 years

Bioactive Keratin is a sulfur-containing protein that is unique in composition and properties. Keratin preparations are actively used in medicine and

cosmetology [12-14, 29]. However, this protein, obtained from the secondary products of the fur-processing industry, may be in demand in animal husbandry as a biologically active additive to the BD of fur-bearing animals. Bioactive Keratin from tow of sheep wool has the following characteristics (Table 2).

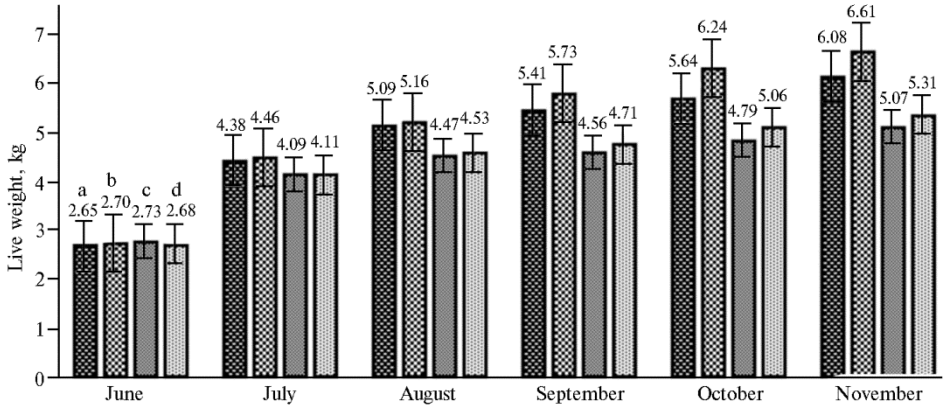

Fig. 1. Body weight dynamics of young silver-black foxes (*Vulpes vulpes* L.) upon application of anthelmintic Niacid-Granules Plus and sulfur-containing feed additive Bioactive Keratin: a — Niacid-Granules Plus, b — Niacid-Granules Plus + Bioactive Keratin, c — intact animals (control), d — Bioactive Keratin (n = 10 per group, AO Saltykovskii Breeding Farm, 2017).

In June, before the start of the experiment, the mass of 2-month-old animals in all groups was approximately the same (Fig. 1), statistically significant differences between the groups were not revealed. After 1 month, the live weight of animals in all groups increased on average by 1.50-1.65 times compared with the previous indicators. At the same time, significant differences appeared between the mass of animals from Group I who received Niacid-Granules Plus and intact animals from Group III (control) ($t_{fact.} = 3.05 > t_{table} = 2.1$ at $p = 0.05$). When comparing weight of animals from Groups II and III, it was found that with the combined use of Niacid-Granules Plus and Bioactive Keratin, the mass of young animals in Group II was 9.1% higher than in the control group and approximately 2% higher than the indicator in the case of using only the anthelmintic preparation (respectively, $t_{fact.} = 7.40 > t_{table} = 2.1$ at $p = 0.05$ and $t_{fact.} = 0.81 < t_{table} = 2.1$ at $p = 0.05$). Comparison of the live weight of animals in Groups II and IV also made it possible to establish statistically significant differences between them ($t_{fact.} = 5.46 > t_{table} = 2.1$ at $p = 0.05$). There were no such differences between Groups III and IV ($t_{fact.} = 0.34 < t_{table} = 2.1$ at $p = 0.05$). The obtained results reliably indicate the maximum positive effect (increase in the live weight of young animals) with the combined use of the preparations Niacid-Granules Plus and Bioactive Keratin. By the end of the observation period, when comparing the average weight of animals from Group I receiving the anthelmintic preparation and from the control Group III, reliable ($t_{fact.} = 9.34 > t_{table} = 2.1$ at $p = 0.05$) differences (19.9% excess) were revealed. Between Groups II (a combination of two preparation) and IV (using only Bioactive Keratin), there were also significant ($t_{fact.} = 10.11 > t_{table} = 2.1$ at $p = 0.05$) differences in favor of the joint use of the preparations (24.5% increase).

The indicators characterizing the growth rate of young silver-black foxes are presented in Table 3.

A general clinical blood test, which allows making a general assessment of the physiological status of animals, showed (Table 4) that at the beginning of the experiment (before using the preparations), despite some fluctuations, the

indices in the groups did not differ significantly. Thus, the content of hemoglobin, which is responsible for the transport of oxygen from the lungs to tissues and organs, ranged from 7.5 to 8.6%, red blood cells from 4.0 to 4.6 million/ml, white blood cells from 13.1 to 14.9 thousand/ml. It should be noted that at the beginning of the experiment, the young animals were not yet treated with anthelmintic drugs and the obtained values, in all probability, indicate the presence of a weak toxocariasis infestation, the cause of which could be infection both in utero and with mother's milk or through swallowing infective eggs with feed or water [30]. It is known that during helminthiases, the content of hemoglobin in the blood of fur-bearing animals decreases due to blood loss because of posthemorrhagic anemia caused by Toxocara feeding on blood, which damage the intestinal membrane and other internal organs [17, 31].

3. Body weight gain in young silver-black foxes (*Vulpes vulpes* L.) upon application of anthelmintic Niacid-Granules Plus and sulfur-containing feed additive Bioactive Keratin (M±SEM, n = 10 per group, AO Saltykovskii Breeding Farm, 2017)

Groups	Absolute,kg	Relative, %	Daily, g
I (Niacid-Granules Plus)	3.4±0.1	78.6±5.7	114.3±9.0
II (Niacid-Granules Plus + Bioactive Keratin)	3.9±0.2	84.0±6.4	130.3±11.5
III (intact animals, control)	2.3±0.1	60.0±5.3	78.0±5.5
IV (Bioactive Keratin)	2.6±0.1	65.8±5.6	87.7±5.7

N o t e. For a description of drug application scheme in the groups, see the Techniques section.

4. Clinical blood test results of young silver-black foxes (*Vulpes vulpes* L.) upon application of anthelmintic Niacid-Granules Plus and sulfur-containing feed additive Bioactive Keratin (M±SEM, n = 10 per group, AO Saltykovskii Breeding Farm, 2017

Groups	Начало опыта (1-е сут)			Окончание опыта (210-е сут)		
	HGB, g/%	RBC,×10^6/ml	WBC, ×10^3/ml	HGB, g/%	RBC, ×10^6/ml	WBC, ×10^3/ml
I (NGP)	7.9±0.7	4.2±0.3	13.8±0.9	13.2±1.1	7.3±0.6	6.4±0.5
II (NGP + BK)	8.4±0.6	4.0±0.4	13.6±1.2	13.9±1.2	7.7±0.6	5.3±0.3
III (IA, control)	8.2±0.6	4.4±0.2	14.4±1.0	7.0±0.5	3.9±0.4	14.8±1.0
IV (BK)	8.0±0.3	4.3±0.3	14.1±1.2	7.3±0.4	4.0±0.4	14.4±1.0

N o t e. NGP — Niacid-Granules Plus, NGP + BK — Niacid-Granules Plus + Bioactive Keratin, IA — intact animals, BK — Bioactive Keratin; HGB — hemoglobin, RBC — red blood cells, WBC — white blood cells. For a description of drug application scheme in the groups, see the Techniques section.

After anthelmintic treatment with Niacid-Granules Plus (separately and in combination with a sulfur-containing keratin additive), hematological parameters began to change. In Group I, where only anthelmintic preparation was used, the hemoglobin content increased by 1.7 times, while in Group III (control), by day 210, it decreased by 14.6% compared with the initial one ($t_{fact.}$ = 1.30 < t_{table} = 2.1 at p = 0.05). The established fact indicates an increase in infestation without deworming of young animals. In Group II, where bioactive keratin was used together with the preparation Niacid-Granules Plus, the hemoglobin level increased by 1.9 times. In Group IV, where animals received only bioactive keratin, the hemoglobin level by the end of the experiment decreased by 8.75% ($t_{\text{fact.}}$ = 1.40 < t_{table} = 2.1 at p = 0.05) from the initial one.

The obtained results indicate that the preparation Bioactive Keratin, used as a feed additive, somewhat inhibited the destruction of red blood cells, and also acted as a detoxifier. Red blood cells fulfill the transport function, providing the organism with oxygen and utilizing carbon dioxide. The study of red blood cells is included in the general blood test during the initial diagnosis of many diseases, including parasitic ones [17, 31].

According to the obtained data, the number of red blood cells in the blood

of 2-month-old silver-black foxes prior to deworming ranged from 4.0-4.6 million/ml. Apparently, these values characterize the presence of anemia as a consequence of pathological processes in the body of young animals that are most susceptible to the effects of toxocariasis pathogens. In this case, anemia can also develop due to a lack of iron, vitamin B_{12}, and folic acid [4].

Upon anthelmintic use, the red blood cell counts in of young silver-black foxes began to increase. Thus, in Group I (Niacid-Granules Plus), by the end of the experiment, it increased by 73.8% ($t_{fact.} = 4.62 > t_{table} = 2.1$ at $p = 0.05$), while in Group III (control), it decreased by 9.3% ($t_{fact.} = 1.12 < t_{table} = 2.1$ at $p = 0.05$). With the combination of anthelmintic and feed additives, the same indicator increased by 66.7% ($t_{fact} = 5.13 > t_{table} = 2.1$ at $p = 0.05$). In Group IV, where animals received only a feed additive, the number of red blood cells in the blood decreased by 7.0% by the end of the experiment ($t_{fact} = 0.60 < t_{table} = 2.1$ at $p = 0.05$) from the initial one. Obviously, the peptides formed during the hydrolytic cleavage of bio-additives in the intestines of fur-bearing animals prevent the destruction of red blood cells.

The number of leukocytes in the blood is one of the most important indicators of an animal's state of health. The main function of leukocytes is to detect a foreign agent and neutralize it; these blood cells are the first line of defense of the body encountered by the pathogens colonizing it, including helminths [30, 31]. The content of leukocytes in the blood of young animals before the start of the experiment ranged from 13.4 to 14.4 thousand/ml (see Table 4). The authors consider these initial data as an indication of the presence of a pathological process in the body of young animals, which is associated with the presence of helminths (since the anthelmintic treatment of animals at that time was not yet conducted). In Groups I and II (see Table 4), the number of leukocytes gradually decreased. In Group IV, where animals received only Bioactive Keratin, the number of leukocytes was 2.1% higher than at the beginning of the experiment ($t_{fact} = 0.19 < t_{table} = 2.1$ at $p = 0.05$), but at the same time, it is 2.7% lower than that of animals from Group III ($t_{fact} = 0.28 < t_{table} = 2.1$ at $p = 0.05$). With the combined use of the anthelmintic preparation and bio-additive (Group II), the content of leukocytes in the blood of young animals decreased by 2.6 times. In addition, it is noteworthy that bioactive keratin, together with an antihelminthic preparation, contributes to the normalization of the composition of blood corpuscles.

Niacid-Granules Plus had a pronounced effect on skin area, it increased by 18.1% ($t_{fact} = 22.60 > t_{table} = 2.1$ at $p = 0.05$) compared to Group III (control), (Table 5).

5. Skin area of young silver-black foxes (*Vulpes vulpes* L.) upon application of anthelmintic Niacid-Granules Plus and sulfur-containing feed additive Bioactive Keratin (*M*±SEM, *n* = 10 per group, AO Saltykovskii Breeding Farm, 2018)

Groups	Area, cm^2
I (Niacid-Granules Plus)	2152.0±9.5
II (Niacid-Granules Plus + Bioactive Keratin)	2198.0±11.0*
III (intact animals, control)	1856.0±9.0
IV (Bioactive Keratin)	1909.0±10.3

N o t e. For a description of drug application scheme in the groups, see the Techniques section.
* Differences with control are statistically significant at p = 0.05.

Combination of bioactive keratin and anthelmintic preparation was more effective in terms of skin area, it was 18.4% higher ($t_{fact} = 19.20 > t_{table} = 2.1$ at $p = 0.05$) than in Group III (control). Dietary bioactive keratin without deworming ensured an increase in the area of skins by 2.7% ($t_{fact} = 3.87 > t_{table} = 2.1$ at

p = 0.05) compared to Group III. Between Groups II and IV, this indicator differed by 15.1% statistically significantly ($t_{fact.}$ = 24.60 > t_{table} = 2.1 at p = 0.05).

The use of drugs affected the quality of the hair. The greatest length of all hair categories was characteristic of the lateral area of the skins in all groups, the smallest length in fur and transient hair was noted in the rump area, in the guard and aligning hair in the spinal part (Table 6).

6. Skin hair length (mm) **of young silver-black foxes (*Vulpes vulpes* L.) upon application of anthelmintic Niacid-Granules Plus and sulfur-containing feed additive Bioactive Keratin (***M***±SEM,** ***n*** = 50, AO Saltykovskii Breeding Farm, 2018)

Groups	Category of hair	Locations		
		spine	side	rump
I (Niacid-Granules Plus)	Down hair	44.7±0.1*	46.3±0.5*	43.0±0.8*
	Awn hair	52.8±0.3	53.2±0.3	52.4±0.6
	Guard hair	69.8±0.8	75.7±0.8	70.5±0.9
	Guide hair	73.0±0.7	82.0±0.7	75.7±0.6
II (Niacid-Granules Plus + Bioactive Keratin)	Down hair	46.9±0.7*	49.8±0.4*	45.9±0.8*
	Awn hair	53.6±0.4	56.9±0.5	53.2±0.3
	Guard hair	72.2±0.7	77.2±0.6	72.9±0.7
	Guide hair	74.1±0.3	84.5±0.2	82.3±0.6
III (intact animals, control)	Down hair	31.4±0.2	32.8±0.4	32.0±0.4
	Awn hair	40.2±0.1	41.7±0.6	42.1±0.2
	Guard hair	37.8±0.3	26.6±0.2	27.2±0.4
	Guide hair	62.1±0.2	54.3±0.7	57.4±0.6
IV (Bioactive Keratin)	Down hair	36.6±0.1	38.8±0.6	37.4±0.4
	Awn hair	44.0±0.2	45.6±0.4	44.1±0.2
	Guard hair	48.3±0.2	36.2±0.2	31.8±0.7
	Guide hair	65.5±0.4	58.7±0.6	60.2±0.4

N o t e. For a description of drug application scheme in the groups, see the Techniques section.
* Differences with control are statistically significant at p = 0.05.

The length of down hair on the side of the skins in Groups I and III significantly increased by 4.5% ($t_{fact.}$ = 2.80 > t_{table} = 2.1 at p = 0.05) as influenced by using only anthelmintic preparation. In Groups II and IV with the combination of an anthelmintic preparation and a bio-additive, an increase in the length of down hair reached 4.2% ($t_{fact.}$ = 3.50 > t_{table} = 2.1 at p = 0.05). Differences were also characteristic of the remaining topographic areas in which the length of the hair was analyzed (see Table 6).

7. Hair thickness (microns) **on the skins of young silver-black foxes (*Vulpes vulpes* L.) upon application of anthelmintic Niacid-Granules Plus and sulfur-containing feed additive Bioactive Keratin (***M***±SEM,** ***n*** = 50, AO Saltykovskii Breeding Farm, 2018)

Groups	Category of hair	Locations		
		spine	side	rump
I (Niacid-Granules Plus)	Down hair	20.4±0.2	20.3±0.3	21.8±0.4
	Awn hair	47.2±0.7	45.5±0.5	50.2±0.5
	Guard hair	76.9±0.7	72.6±0.7	80.3±0.6
	Guide hair	87.9±0.7	73.8±0.2	94.5±0.6
II (Niacid-Granules Plus + Bioactive Keratin)	Down hair	21.4±0.2	21.2±0.4	22.1±0.3
	Awn hair	49.9±0.8	45.3±0.6	50.0±0.7
	Guard hair	80.3±0.7	75.6±0.6	85.7±0.9
	Guide hair	96.8±0.5	95.7±0.7	97.8±0.9
III (intact animals, control)	Down hair	22.4±0.5	21.7±0.2	23.6±0.7
	Awn hair	36.9±0.2	35.7±0.4	37.1±0.5
	Guard hair	58.4±0.6	59.6±0.6	60.1±0.4
	Guide hair	68.5±0.4	61.1±0.7	59.8±0.6
IV (Bioactive Keratin)	Down hair	24.3±0.6	23.8±0.3	24.8±0.4
	Awn hair	37.6±0.4	37.7±0.3	39.7±0.7
	Guard hair	61.8±0.9	65.1±0.9	69.9±0.3
	Guide hair	71.4±0.6	70.8±0.3	71.8±0.6

N o t e. For a description of drug application scheme in the groups, see the Techniques section.

The thickness of hair (Table 7) in various topographic areas of the skins was studied on the same samples on which the length of the hair was measured. The obtained data enable to conclude that neither the anthelmintic preparation Niacid-Granules Plus, nor its combination with the feed additive Bioactive Keratin affected the thickness of the hair of the skins in comparison with the control ($t_{fact.} = 1.8 < t_{table} = 2.1$ and $t_{fact.} = 1.3 < t_{table} = 2.1$, respectively, at $p = 0.05$). The same was noted for Group IV.

The density of hair on skin was estimated by the number of primary and secondary follicles, as well as by direct counting of all hair categories per unit area (1 cm^2) of samples taken from the rump part of the skin (Table 8).

8. Hair density on the skins of young silver-black foxes (*Vulpes vulpes* L.) upon application of anthelmintic Niacid-Granules Plus and sulfur-containing feed additive Bioactive Keratin (*M*±SEM, *n* = 10, AO Saltykovskii Breeding Farm, 2018)

Groups	Average number of hair follicles per microscope field of view		Total hair numberper unit area (1 cm^2)
	primary	secondary	
I (Niacid-Granules Plus)	14.3	1.4	14322±468
II (Niacid-Granules Plus + Bioactive Keratin)	15.7	1.6	15670±580*
III (intact animals, control)	11.1	1.0	12576±462
IV (Bioactive Keratin)	12.3	1.1	13009±359

N o t e. For a description of drug application scheme in the groups, see the Techniques section.
* Differences with control are statistically significant at p = 0.05.

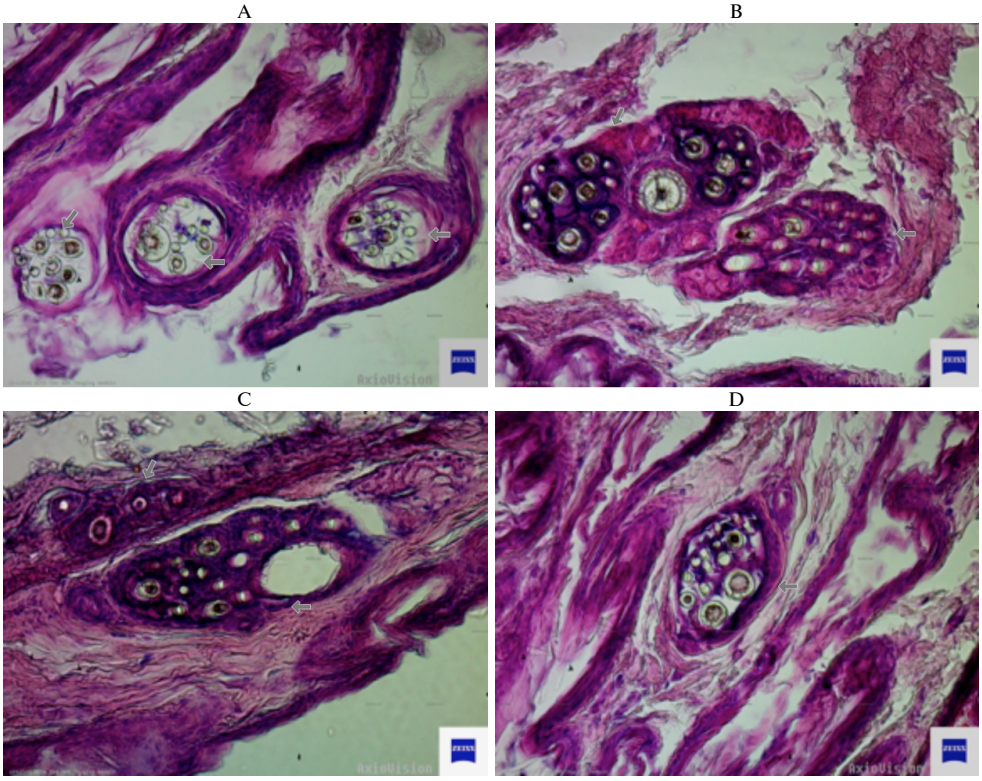

Fig. 2. Horizontal histological sections of the skin tissue of silver-black fox (*Vulpes vulpes* L.) pelt as influenced by anthelmintic Niacid-Granules Plus (A)**, Niacid-Granules Plus in combination with the sulfur-containing feed additive Bioactive Keratin** (B)**, in intact animals (control)** (C) **and when using Bioactive Keratin** (D) AO Saltykovskii Breeding Farm, 2018). Staining with hematoxylin and eosin, magnification ×400; arrows indicate bunches of hair.

The use of Niacid-Granules Plus had a positive effect on the downiness of the skins: the total number of all hair categories per 1 cm^2 was 13.9% higher

($t_{fact.}$ = 2.66 > t_{table} = 2.1 at p = 0.05) than in control. Combination of the anthelmintics and bioactive keratin significantly ($t_{fact.}$ = 4.17 > t_{table} = 2.1 at p = 0.05) increased hair density by 24.6% compared to control, whereas bioactive keratin only by 3.4% ($t_{fact.}$ = 0.74 < t_{table} = 2.1 at p = 0.05). Consequently, the combined application of the studied preparations had the greatest positive effect. It is obvious that the anthelmintic drug contributed to the healing of the young silver-black foxes, due to which bioactive keratin stimulated the growth of the thicker hair to the maximum extent.

Many authors note that it is keratin that stimulates hair growth, increasing their density due to the activation of embryonic follicles [11]. To test this hypothesis, horizontal histological sections were prepared from samples of the same skins taken from the rump part (Fig. 2).

Our findings substantiate application of Niacid-Granules Plus in combination with Bioactive Keratin as an element of the technology for growing slaughtered young silver-black fox to improve the physiological condition of animals and obtain more qualitative skins. Niacid-Granules Plus is recommended to be used 2 times with a 10-day interval at the age of 2 months, and Bioactive Keratin should be added to the main diet in six cycles (5-day courses with 10-day intervals).

Thus, deworming of young silver-black foxes ages 2 months using a new generation of Niacid-Granules Plus drug followed by application of dietary Bioactive Keratin contribute to the accelerated normalization of the physiological status of young silver-black foxes, which is confirmed by clinical indicators of blood, and significantly affect the live weight gain. When using both preparations, the weight of young silver-black foxes increased by 30.4%, the area of the obtained skins by 18.4%, the density of the hair by 24.6% compared to the same parameters for intact animals. This allows us to recommend Niacid-Granules Plus in combination with feed additive Bioactive Keratin for practical use in animal husbandry to improve the well-being of animals and the quality of marketable products obtained from them.

REFERENCES

1. *Canids: foxes, wolves, jackals and dogs. Status survey and conservation action plan.* C. Sillero-Zubiri, M. Hoffmann, D.W. Macdonald (eds.). IUCN, Gland, Switzerland and Cambridge, UK, 2004.
2. Zhang T., Zhong W., Sun W., Wang Z., Sun H., Fan Y., Li G. Effects of dietary fat: carbohydrate ratio on nutrient digestibility, serum parameters, and production performance in male silver foxes (*Vulpes vulpes*) during the winter fur-growing period. *Canadian Journal of Animal Science*, 2017, 97(2): 199-206 (doi: 10.1139/CJAS-2015-0167).
3. Juokslahti T., Korhonen T., Oksanen A. Coccidiosis in farmed silver foxes (*Vulpes vulpes*) and blue foxes (*Alopex lagopus*) in Finland: a case report. *Acta Veterinaria Scandinavica*, 2010, 52(supplement 1): S18 (doi: 10.1186/1751-0147-52-S1-S18).
4. Özkan B. Parasitary infestation in a fox. *Journal of Istanbul Veterinary Sciences*, 2018, 2(1): 14-22 (doi: 10.30704/http-www-jivs-net.388610).
5. Lankas G.R., Gordon L.R. *Toxicology.* In: *Ivermectin and avermectin.* W.C. Campbell (ed.). Springer-Verlag, NY, 1989: 89-112.
6. Taira K., Saeed I., Kapel C.M. Dose-dependent egg excretion in foxes (*Vulpes vulpes*) after a single infection with *Toxocara canis* eggs. *Parasitology Reserch*, 2002, 88(10): 941-943 (doi: 10.1007/s00436-002-0680-x).
7. Magi M., Guardone L., Macchioni F., Prati M.C., Mignone W. Extraintestinal nematodes of the red fox *Vulpes vulpes* in north-west Italy. *Journal of Helminthology*, 2015, 89(4): 506-511 (doi: 10.1017/S0022149X1400025X).
8. Bobova T.A., Kolobov A.V., Zavarzin I.V., Dzhafarov M.Kh., Plakhtinskii V.V., Kuleshova E.S. *Tezisy XIX Mendeleevskogo s"ezda po obshchei i prikladnoi khimii* [Proc. XIX Mendeleev Congress on General and Applied Chemistry]. Volgograd, 2011, vyp. 1: 130 (in Russ.).

9. Dyary H.O. Veterinary anthelmintics and anthelmintic drug resistance. *Journal of Zankoy Sulaimani. Part-A (Pure and Applied Sciences)*, 2016, 18(1): 191-206 (doi: 10.17656/jzs.10463).
10. Prichard R., Ménez C., Lespine A. Moxidectin and the avermectins: consanguinity but not identity. *International Journal of Parasitology: Drugs and Drug Resistance,* 2012, 2: 134-153 (doi: 10.1016/j.ijpddr.2012.04.001).
11. Vasilevich F.I., Sapozhnikova A.I., Okutin A.S., Gordienko I.M., Ruchkina Z.S., Bordachev V.N. Improvement of ferret fur pelt quality by using products of recycling raw materials of animal origin. *Agricultural Biology* [*Sel'skokhozyaistvennaya Biologiya*], 2017, 6(52): 1214-1225 (doi: 10.15389/agrobiology.2017.6.1214eng).
12. Mogosanu G.D., Grumezescu A.M., Chifiriuc M.C. Keratin-based biomaterials for biomedical applications. *Current Drug Targets*, 2014, 15(5): 518-530 (doi: 10.2174/1389450115666140307154143).
13. Kirsner R.S., Cassidy S., Marsh C., Vivas A., Kelly R.J. Use of a keratin-based wound dressing in the management of wounds in a patient with recessive dystrophic epidermolysis bullosa. *Advances in skin and wound care*, 2012, 25(9): 400-403 (doi: 10.1097/01.ASW.0000419404.44947.de).
14. Rouse J.G., Van Dyke M.E. A review of keratin-based biomaterials for biomedical applications. *Materials*, 2010, 3: 999-1014 (doi: 10.3390/ma3020999).
15. Van Heugten E., Van Kempen T.A. Growth performance, carcass characteristics, nutrient digestibility and fecal odorous compounds in growing-finishing pigs fed diets containing hydrolyzed feather meal. *Journal of Animal Science*, 80(1): 171-178 (doi: 10.2527/2002.801171x).
16. Poole L.B. The basics of thiols and cysteines in redox biology and chemistry. *Free Radical Biology and Medicine*, 2015, 80: 148-157 (doi: 10.1016/j.freeradbiomed.2014.11.013).
17. Golubkov V.A. V sbornike: *Ekologiya Yuzhnoi Sibiri i sopredel'nykh territorii* [In: Ecology of Southern Siberia and adjacent territories]. Moscow, 2016: 12 (in Russ.).
18. Dröge W., Breitkreutz R. Glutathione and immune function. *Proceedings of the Nutrition Society*, 2000, 59(4): 595-600 (doi: 10.1017/s0029665100000847).
19. Ghezzi P. Role of glutathione in immunity and inflammation in the lung. *International Journal of General Medicine*, 2011, 4: 105-113 (doi: 10.2147/IJGM.S15618).
20. Wang B., Yang W., McKittrick J., Meyers M.A. Keratin: structure, mechanical properties, occurrence in biological organisms, and efforts at bio inspiration. *Progress in Materials Science*, 2016, 76: 229-318 (doi: 10.1016/j.pmatsci.2015.06.001).
21. Ramms L., Fabris G., Windoffer R., Schwarz N., Springer R., Zhou C., Lazar J., Stiefel S., Hersch N., Schnakenberg U., Magin T.M., Leube R.E., Merkel R., Hoffmann B. Keratins as the main component for the mechanical integrity of keratinocytes. *PNAS USA*, 2013, 110(46): 18513-18518 (doi: 10.1073/pnas.1313491110).
22. Windoffer R., Beil M., Magin T.M., Leube R.E. Cytoskeleton in motion: the dynamics of keratin intermediate filaments in epithelia. *J. Cell Biol.*, 2011, 194(5): 669-678 (doi: 10.1083/jcb.201008095).
23. Dzhafarov M.Kh., Vasilevich F.I. Ecological, physiological and biochemical adaptation in helminth: trends in evolution of anthelminthic chemical agents (review). *Advances in Pharmacology and Pharmacy*, 2014, 2: 30-45.
24. Peng Y., Shi Q., Wang Y., Zhang F., Ji Z., Zhang J. Dietary probiotics have different effects on the composition of fecal microbiota in farmed raccoon dog (*Nyctereutes procyonoides*) and silver fox (*Vulpes vulpes fulva*). *BMC Microbiology*, 2019, 19(1): Article number 109 (doi: 10.1186/s12866-019-1491-x).
25. Sapozhnikova A.I., Kaspar'yants S.A., Mesropova N.V., Gordienko N.M. *Sposob polucheniya keratina. A.c. 2092072 (RF) MKI^6 A 23 K 1/10. № 95117245-13.* Zayavl. 06.10.95. Opubl. 10.10.97. Byul. № 28 [The method of obtaining keratin. A.c. 2092072 (RF) MKI^6 A 23 K 1/10. № 95117245-13. Appl. 06.10.95. Publ. 10.10.97. Bul. № 28] (in Russ.).
26. Prozorovskii V.B., Prozorovskii M., Demchenko V.M. *Farmakologiya i toksikologiya*, 1978, 41(4): 497-502 (in Russ.).
27. Borovikov V. *STATISTICA. Iskusstvo analiza dannykh na komp'yutere* [STATISTICA. The art of computer data analysis]. St. Petersburg, 2003 (in Russ.).
28. Borovkov A.A. *Matematicheskaya statistika. Otsenka parametrov. Proverka gipotez* [Math statistics. Estimation of parameters. Hypothesis testing]. Moscow, 1984 (in Russ.).
29. Esepenok K.V., Sapozhnikova A.I., Mirzayev M.N. Safety assessment of the "Niacid-granules plus" product and the "Bioactive keratin" sulfur-containing feed additive. *Materials of the International Conference «Scientific research of the SCO countries: synergy and integration»*. Beijing, 2019: 140-148 (doi: 10.34660/INF.2019.16.36671).
30. Napisanova L.A., Zhdanova O.B., Okulova I.I., Ashikhmin S.P., Berezina Yu.A., Chasovskikh O.V. *Rossiiskii parazitologicheskii zhurnal*, 2016, 2: 210-216 (in Russ.).
31. Sanzhieva S.E. *Agrarnyi vestnik Urala*, 2010, 4: 56-58 (in Russ.).